



RADIOLOGY

For the Pain Boards

Spine Imaging Pearls

STIR Sequence

Designed to **suppress signal from fat**, enhances the signal from tissue with long T1 and T2 relaxation times, such as **neoplastic and inflammatory tissues**

Bone Scan

Bone scan and white cell scan (WBC) may be used to demonstrate increased uptake at the site of **infection**, and are more sensitive than plain film and CT, however **lacks specificity**

PET and PET/CT

PET possesses **high sensitivity in detecting spondylodiscitis**. As such infectious spondylodiscitis can virtually be excluded in a negative scan. Dual imaging with PET/CT may thus become the imaging modality of choice

Computed Tomography

CT is the modality of choice for bone and abnormal calcification assessment. CT requires intravenous iodine contrast in case of suspected infection.

Modic Type 1

- Low signal intensity on T1WI and high on T2WI,
 - Representing **fibrovascular tissue, inflammatory changes, and perhaps edema** (may be chronic or acute)
- There is a correlation between low back pain and Modic changes, especially Modic type 1.

Diffusion clawing- In patients with type 1, signal changes of the vertebral disk space, a **claw sign** is highly suggestive of degeneration and its absence strongly suggests diskitis/osteomyelitis.

Modic Type 2

Modic Type 2 is seen as high signal intensity on T1WI and isointense or high on T2WI, representing **bone marrow replacement by fat**.

Modic Type 3

Modic Type 3 is seen as low signal intensity on T1WI and low on T2WI, representing **reactive osteosclerosis**.

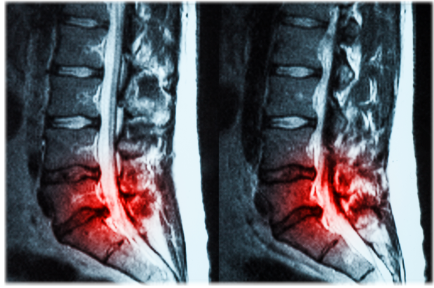
Schmorl's nodes

Protrusions of disc material into the surface of the vertebral body, which may contact the marrow of the vertebra and lead to inflammation. The protrusions are also associated with necrosis of the vertebral bone.

Protrusion, Extrusion & Sequestration

Protrusion

The distance between the edges of the disc herniation is less than the distance between the edges of the base.



Post Operative Imaging

- MRI is the modality of choice for assessment of discectomies
- Determination of time elapsed after surgery is particularly important, since findings in the early postoperative period (six months) require cautious evaluation. However, MRI is indicated during this period if the patient presents with failed back surgery syndrome.
- For non-contrast MRI images, early postoperative changes following discectomy may simulate the previously removed herniated material as a result of the disruption in the fibrous annulus and the presence of epidural edema.¹⁰
- Following contrast administration, the homogeneous enhancement of this fibrosis and granulation tissue explains the observed mass effect that will progressively decrease



Extrusion

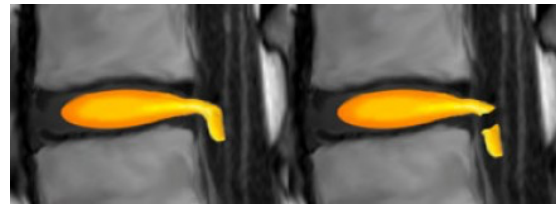
When the distance between the edges of the disc material is greater than the distance at the base.

Extrusion is associated with a defect in the annulus fibrosus and are usually non-contained.

Sequestration

The term sequestration is used to indicate that the displaced disc material has lost continuity with the parent disc.

Extrusion vs. Sequestration



Central Herniations

Since the posterior longitudinal ligament (PLL) is at its thickest in this region, the disc usually herniates slightly to the left or right of this central zone.

Subarticular Herniations

Because the PLL is not as thick in this region, this is the **number one region for disc herniations**.

Foraminal Herniations

It is **rare** for a disc to herniate into the intervertebral foramen. Only 5% to 10% of all disc herniation occur here or farther out. This is often very troublesome for the patient.

This is because the 'Dorsal Root Ganglion' (DRG) lives in this zone resulting in severe pain, sciatica and nerve cell damage.

Extraforaminal Herniations

Disc herniations in this region are uncommon.

HIZ (High Intensity Zone) may represent:

- An area of healing (Granulation tissue) within the disc and wall of the disc.
- An accumulation of breakdown products within the disc and disc wall which may or may not be irritant to neighboring structures.
- It may be associated with bulging of the disc wall (Disc Protrusion), leakage of products from within the disc and or a small tear in the wall of the disc.
- bright white signal on T2W images in the posterior annulus of the disc and represents a fissure/tear in the posterior annulus.